

See discussions, stats, and author profiles for this publication at: <https://www.researchgate.net/publication/372828066>

Femoroplasty as a palliative treatment option For pain Due to metastasis and Fractures in cancer patients

Article · August 2023

CITATIONS

0

READS

13

9 authors, including:



Victor Silva

Centro Medico Zambrano Hellion

29 PUBLICATIONS 24 CITATIONS

SEE PROFILE



Ignacio Reyes Torres

Hospital Christus Muguerza Saltillo

6 PUBLICATIONS 6 CITATIONS

SEE PROFILE



Anna Gisse López

Clinica del dolor La Paz

8 PUBLICATIONS 1 CITATION

SEE PROFILE

Some of the authors of this publication are also working on these related projects:



Facial Pain View project

FEMOROPLASTY AS A PALLIATIVE TREATMENT OPTION FOR PAIN DUE TO METASTASIS AND FRACTURES IN CANCER PATIENTS: A CASE REPORT

Victor M. Silva-Ortiz, MD¹, Ignacio Reyes, MD², Anna Gisse Lopez, MD³, Alsacia Gonzalez, MD¹, Dulce Ramirez, MD¹, Jocelyn Reyes Armendáriz, MD¹, Paul Alejandro Medina, MD¹, Maria Laura Escobar, MD⁴, and Ricardo Plancarte, MD⁵

Background: Bone metastases are a frequent condition in cancer patients. They tend to manifest mainly in the long bones and spine, causing pain and reducing the patient's quality of life. Percutaneous femoroplasty has been proposed to improve pain and bone stability in these patients by injecting polymethylmethacrylate (PMMA) into the affected areas. This report aims to demonstrate this technique's benefits in stabilizing the bone and the hip joint by consolidating fractures due to bone metastases, alleviating cancer pain, and improving quality of life.

Case Report: A 74-year-old female patient diagnosed with breast cancer and metastasis to the spine and femoral head, with severe oncological pain in the right hip region, is presented. In Tronzo's classification, computed tomography showed a type I fracture in the right hip. Fluoroscopy-guided femoroplasty with bone cementation was performed, presenting significant pain relief in the short, medium, and long term and improved quality of life.

Conclusion: Femoroplasty as a palliative technique to improve bone cancer pain is an important tool to consider when conservative management does not provide favorable results in pain and functionality, being a safe procedure for patients who cannot undergo major surgery.

Key words: Bone pain, cancer pain, case report, femoroplasty, interventional pain

BACKGROUND

Bone metastases are frequent in cancer patients, usually observed in advanced stages and with a high incidence in breast, prostate, and lung cancers. They tend to manifest mainly in the long bones and spine, causing pain and reducing the patient's quality of life. Despite the different conservative and pharmacological treatments for painful bone fractures, developing a minimally invasive 11-treatment with favorable results is necessary. Percutaneous femoroplasty has been

proposed to improve pain and bone stability in these patients by injecting polymethylmethacrylate (1). This report aims to demonstrate this technique's benefits in stabilizing the bone and the hip joint by consolidating fractures due to bone metastases, alleviating cancer pain, and improving quality of life.

CASE REPORT

We present the case of a 74-year-old woman diagnosed with breast cancer in 2008, treated with che-

From: ¹Pain Management Department, Hospital Zambrano Hellion, Tec Salud. San Pedro Garza García, Nuevo León; ²Acute Pain Department Christus Muguerza Hospital Saltillo; ³Pain Clinic. La Paz, Baja California Sur; ⁴Westhill University, Mexico City; ⁵National Cancer Center, Mexico City

Corresponding Author: Victor M. Silva-Ortiz, MD, E-mail: drvictorsilva@gmail.com

Disclaimer: There was no external funding in the preparation of this manuscript.

Conflict of interest: Each author certifies that he or she, or a member of his or her immediate family, has no commercial association (i.e., consultancies, stock ownership, equity interest, patent/licensing arrangements, etc.) that might pose a conflict of interest in connection with the submitted manuscript.

Patient consent for publication: Our institutional policy exempts us from needing informed consent.

Authors adhere to the CARE Guidelines for writing case reports and have provided the CARE Checklist to the journal editor.

Accepted: 2023-03-27, Published: 2023-07-31

motherapy and radiotherapy, and a history of 3 breast surgeries in addition to presenting metastases to the spine and femoral head. Medical care was provided at home due to severe cancer pain in the right hip region, with a baseline Visual Analog Scale (VAS) score of 7 of 10, incidental VAS score of 9 of 10 for the somatic component, 2 months of evolution, under treatment with transdermal buprenorphine 240 µg/day, tramadol with paracetamol as a rescue medication, with poor response. Due to the pain intensity, the patient remained in bed for a longer time and could not tolerate a sitting position. The results of the functional status assessment scales for cancer patients were recorded: Karnofsky scale (KPS) 40, Eastern Cooperative Oncology Group (ECOG) scale 4, Palliative Performance Scale (PPS) 40, and the Palliative Prognostic Index (PPI) 3.5. Computed tomography (CT) with 3D reconstruction showed lytic and blastic lesions in the right femur resulting in 9 points on Mirel's scale (which evaluates the risk of pathological fracture) (Fig. 1).

The performance of a femoroplasty was proposed, and the probable risks and complications were communicated to the patient and caregivers, who accepted the procedure. The patient was admitted to the operating room in July 2021 with a baseline VAS 10 of 10, referring to an increase in pain intensity for hours before the admission; an external rotation was observed of the right pelvic limb, as well as shortening, for which a simple x-ray of the right hip was taken and a type III fracture was observed according to the Tronzo (inter-trochanteric) classification for hip fractures.

According to the technique described by Plancarte et al (1), the C-arm was oriented so that the puncture site could be lateral to the femur, with a craniocaudal angle

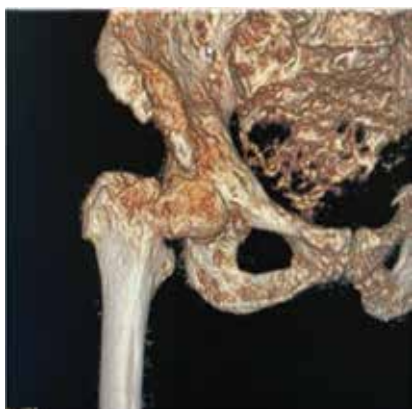


Fig. 1. Computed axial tomography (CT) of the hip with 3D reconstruction.

tilt of 20 to 30 degrees (1). The C-arm was rotated until the neck, femoral head, and greater trochanter were visualized as an oval (tunnel view). Skin and subcutaneous tissue were infiltrated with 1% lidocaine, and an 11-gauge x 10-cm Jamshidi needle was inserted into the upper area of the greater trochanter in a cephalic direction to stabilize the fracture, advancing through the cortical region of the trochanter using lateral and tunnel projection as a guide. The Jamshidi needle was advanced until the tip was at the junction of the anterior and medial thirds of the femoral head.

Subsequently, second and third Jamshidi needles were placed in the medial and inferior areas of the greater trochanter, advancing through the cortical region of the trochanter to place the tip of both styles at the level of the junction of the anterior and medial third of the femoral head.

Once the 3 Jamshidi needles were placed, their locations were confirmed using 3 mL of non-ionic contrast medium to assess the filling pattern and identify leaks into the joint space or vasculature. Having an adequate position of the needles, polymethylmethacrylate (PMMA) was injected (2.5 mL per needle) in the femoral head and neck area, stopping once the distribution of the cement covered the desired area, controlled with anteroposterior (AP) and lateral projections. Using this cement spread as an anchor, the needles were withdrawn while cement was injected along the path in order to leave a "cement nail" to stabilize the bone structures (Fig. 3). The patient was taken to the recovery room and remained neurologically and cardiovascularly intact with no deficits reported and no complications noted.

Follow-up was carried out at one week, one month, and 3 months (Fig. 4). The patient referred to a considerable improvement in pain (50%) in the immediate postoperative period, presenting maximum pain relief 3 days after the procedure (60%). In the assessment

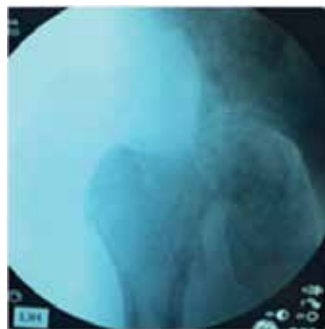

Fig. 2. Fracture reduction.

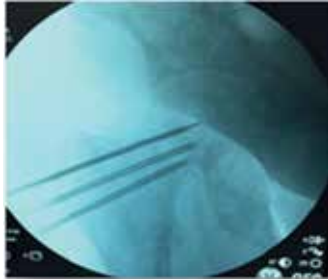


Fig. 3. Femoroplasty needle placement.

at one month, the patient reported baseline VAS 3 of 10, incidental VAS 5 of 10, and overall improvement in clinical outcome in patient satisfaction, functionality and quality of life (KPS 40, ECOG 3, PPS 50, and the PPI 3.5). At the 3-month follow-up, the patient reported tolerating more time in a sitting position as well as the ability to walk short distances with support (caregiver or walker), KPS 60 assessment, ECOG 3, PPS 50, and the PPI 2.5, referring to a baseline VAS: 2 of 10 and incidental VAS 4 of 10 which she considered tolerable supported by oral treatment based on tramadol with paracetamol and pregabalin 75 mg every 24 hours.

It is important to mention that in this type of approach with 3 or more Jamshidi needles, a possibility in the palliative patient is leaving the needles inside the femur after the cement injection. Hence, the needles work like nails to offer greater stability, and the hub of the needle can later be cut.

DISCUSSION

Bone pain may be responsible for limited mobility in patients with bone metastases, reflected in a higher risk of infection, ulcer formation, and a significant decrease in patients' quality of life.

In the present case report, our patient reported significant pain and functional deterioration, already managed by conventional treatment, including radiotherapy, which doesn't have an immediate effect or effectively repair the osteolytic damage caused by bone metastases. Within the therapeutic options indicated by the literature, tumor resection with internal fixation or proximal femoral resection with hip replacement is considered. As a palliative alternative, femoroplasty is a tool to consider for patients who cannot tolerate these high-risk surgical procedures.

Percutaneous bone cementation has been reported in different parts of the skeletal system, such as the tibia, pelvis, and various support points in the acetabulum, ilium, and sacrum, with approximately 90% pain relief

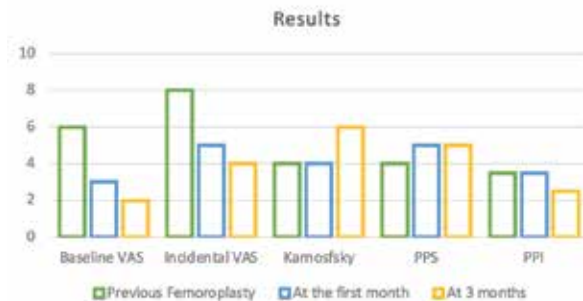

Fig. 4. Results of scales before femoroplasty and follow-up. Abbreviations: PPI, Palliative Prognostic Index; PPS, Palliative Performance Scale; VAS, Visual Analog Scale

(2). This may be because PMMA provides lytic activity due to the thermal action produced by the cement, which reduces metastatic activity, suggesting that it probably inhibits nociceptors, thus relieving pain, as in vertebroplasties.

Feng et al (3) assessed functionality using the Barthel index in 16 cancer patients with bone metastases who underwent CT-guided femoroplasty; the Barthel index score increased significantly from 44.06 ± 9.53 before the procedure to 69.06 ± 8.61 at 7 days and 83.13 ± 6.55 at 6 months of follow-up. Plancarte et al (4), in 2014, performed femoroplasty on 80 cancer patients with metastases to the femur, reporting significant improvement in functionality scales, pain, and other variables such as appetite, fatigue, and insomnia after the procedure.

In the case presented, we can see that after 3 months of follow-up, the patient improved even in the KPS 60, ECOG 3, PPS 50, and PPI 2.5, without complications, which have been described as osteomyelitis, cement leakage, nerve or vascular injury, persistent pain, incident fracture after cementoplasty, rejection of PMMA and avascular necrosis of the femoral head due to cement leakage into the circumflex artery.

CONCLUSION

As a palliative technique to improve bone cancer pain, femoroplasty is an important tool to consider when conservative management does not provide favorable results, both in terms of pain and functionality, and is a safe procedure for patients who cannot undergo major surgery. Despite being a technique described almost 10 years ago, there is limited evidence of the overall outcome or for its effectiveness, considering the prevalence of bone pain secondary to femoral metastases.

Author Contributions

VMSO: Writing, editing, literature review.
IR: Writing, editing, literature review, RP: Writing, editing, literature review, AGL: Writing, editing, lit-

erature review AG: Writing, editing, literature review.
DR: Writing, editing, literature review. PAMR: Writing, editing, literature review.

REFERENCES

1. Plancarte-Sánchez R, Guajardo-Rosas, J, Cerezo-Camacho O, et al. Femoroplasty: A new option for femur metastasis. *Pain Pract* 2012; 13:409-415.
2. Kim WS, Kim KH. Percutaneous osteoplasty for painful bony lesions: A technical survey. *Korean J Pain* 2021; 34:375-393.
3. Feng H, Wang J, Guo P, Xu J, Chen W, Zhang Y. CT-guided percutaneous femoroplasty (PFP) for the treatment of proximal femoral metastases. *Pain Physician* 2016; 19:E767-E773.
4. Plancarte R, Guajardo J, Meneses-Garcia A, et al. Clinical benefits of femoroplasty: A nonsurgical alternative for the management of femoral metastases. *Pain Physician* 2014; 17:227-234.